

Review Article

Cavernous sinus thrombosis of odontogenic origin

Nilton Alves¹, Naira Figueiredo Deana²

¹CIMA Research Group, Faculty of Dentistry, Universidad de La Frontera, Temuco, Chile; ²Private Physical Therapist, Temuco, Chile

Received October 27, 2015; Accepted March 5, 2016; Epub March 15, 2016; Published March 30, 2016

Abstract: The aim of this study was to review the literature regarding septic cavernous sinus thrombosis of odontogenic origin. Searches were made of the electronic databases and reference lists of the pertinent articles between 1990 and 2015. The search strategy produced 161 references, which included 15 studies that fulfilled the inclusion criteria. The literature review showed that the odontogenic focus occurs most frequently from a dental abscess and is related mainly to the third molar followed by the second molar. Dissemination of the infection was observed for the buccal, pterygomandibular, infratemporal and parapharyngeal spaces. Swelling was the most frequent symptom and *pseudomonas aeruginosa* was the most common infectious agent. Drug treatment has generally been administered using combinations, with vancomycin being the most frequently used. In surgical treatment, patients underwent abscess drainage and dental extraction. It was observed that fewer than 50% of the patients had fully recovered prior to hospital discharge. Considering that odontogenic infections can act as primary sources, dentists are among the professionals responsible not only for diagnosis, but also for prophylaxis and referral for specialized medical treatment.

Keywords: Cavernous sinus thrombosis, odontogenic focus, infection disease

Introduction

The cavernous sinus (CS) is an important sinus for drainage of the brain. It is dual, symmetrical, and located laterally to the sella turcica of the sphenoid bone in the middle cranial fossa. The CS is related to the internal carotid artery, trigeminal ganglion as well as the oculomotor, trochlear, ophthalmic, maxillary and abducens nerves [1]. It communicates with the facial vein via the angular and ophthalmic veins as well as with the pterygoid plexus.

Dissemination of a dental infection via the blood vessels occurs when the pathogenic microorganisms circulate through the veins that drain the infected oral cavity for tissues from other regions, like the cavernous sinus. This occurs by virtue of the absence of valves in the veins in that region, allowing the blood to circulate both outside and inside the cranial cavity [1]. The absence of valves in the cerebral veins even enables the infection to spread to the contralateral CS, other intracranial sinuses and even makes possible the development of meningitis [1-3].

Cavernous sinus thrombosis (CST) is a serious encephalic complication of cranial, cervical or facial infections that can progress to death if not treated in time [1]. Clinical diagnosis for this disease is difficult due to its similarity to other infections that attack the proximities of the orbit [4]. Because septic CST is a complication of infections that can be of odontogenic origin, we believe it is very important for dentists to be familiar with this pathology.

In this work we performed a literature review and discussion of the bibliography regarding septic CST, including its etiopathogeny, diagnosis and prophylaxis.

Materials and methods

A systematic search of the literature was performed on Medline, Pubmed, Scopus, Web of Science and Scielo of all peer-reviewed studies between 1990 and 2015 for cavernous sinus thrombosis of dental origin. The selection of keywords was based on DECs (Bireme's Health Sciences Descriptors) and included the following descriptors in English, Spanish and

Cavernous sinus thrombosis

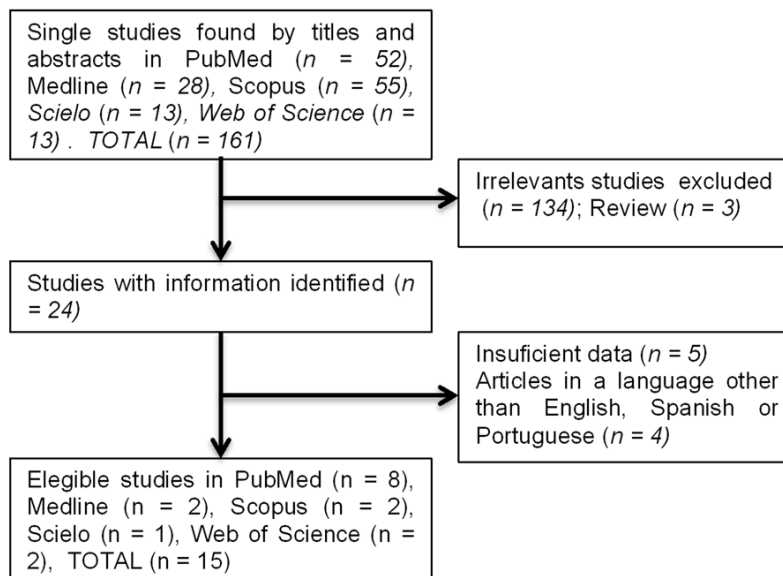


Figure 1. Flow chart shows how articles were selected.

Portuguese: “Cavernous sinus thrombosis” OR “Septic Cavernous sinus thrombosis” OR “Cavernous sinus thrombophlebitis” OR “Septic Cavernous sinus thrombophlebitis” and “odontogenic infection” OR “dental infection”. The most recent date for this search was August 8, 2015.

The inclusion criteria were as follows: (1) articles identified by relevant titles and abstracts for CST of odontogenic origin; (2) articles written in English, Spanish and Portuguese; (3) full texts of published studies and case studies. The manuscript references included were also reviewed. The exclusion criteria were as follows: (1) studies that contained previously published data and (2) no data of interest reported (primary source, symptoms, bacteria, treatment, and outcome).

Results

The initial search strategy produced 161 references. The titles and abstracts were examined and after reading the text 15 studies were selected that fulfilled the inclusion criteria (**Figure 1**) and a total of 16 patients, aged between 07 and 69 years, 11 men and 5 women. **Table 1** summarizes the characteristics of the studies included.

Primary dental focus

The odontogenic focus occurred most frequently from a dental abscess and was related main-

ly to the third molar followed by the second molar, there being no predilection for side or maxilla/mandible (**Figure 2**). Caries were observed in 15% of the patients, followed by gingival inflammation (10%), periodontitis (5%) and periapical lesion (5%). We observed no tendency toward a region (maxilla or mandible).

Frequency of symptoms

Analyzing the most frequent symptoms, we found swelling (100%) followed by fever (68.75%), palsy of the cranial nerve (III, IV and VI) (66.7%), proptosis (62.5%), ptosis (60%), chemosis (56.25%) and headache (53.4%). Other symptoms reported by patients are listed in **Figure 3**.

Infectious agents

In terms of the infectious agents, we found that *Pseudomonas aeruginosa* represented 25%, followed by *Staphylococcus aureus* and *Streptococcus anginosus* each with 16.68%, *Streptococcus constellatus* (8.33%), *Streptococcus milleri* (8.33%), coagulase-negative staphylococci (8.33%) and other types of staphylococci (8.33%).

Drug and surgery treatments

With regard to the drug treatment, we observed that vancomycin was the most frequently used drug, followed by ceftriaxone, clindamycin and metronidazole (**Figure 4**). Heparin was used in 43.75% of the patients. In surgeries 91.7% of the patients underwent abscess drainage, 83.4% dental extraction, 16.6% were intubated, 8.3% were tracheostomized and 8.3% underwent decompression surgery.

Dissemination of the infection by cranial spaces

According to the authors, dissemination of the infection via spaces can be seen in **Table 2**. Dissemination via the pterygomandibular space was observed in 21.43%, infratemporal in 21.43%, parapharyngeal 21.43%, buccal

Cavernous sinus thrombosis

Table 1. Summary of the characteristics of each clinical case reported in the studies

Author	Patient age	Patient sex	Primary source	Microbiology	Current Therapy		Outcome
					Antibiotics	Surgery	
Kiddee et al. [5]	49	Male	Lower and upper third molars, right side	<i>Pseudomonas Aeruginosa</i>	Ceftazidime and clindamycin	Abscess drainage; dental extraction	Good
Prabhu et al. [6]	35	Female	Upper second molar, left side	<i>Staphylococcus; Klebsiella</i>	Cefotaxime, ceftriaxone and ampicillin-sulbactam combination; metronidazole	Incision and drainage left submandibular, submasseteric, pterygomandibular and buccal spaces; dental extraction; patient was intubated	Good; Persistence of Horner's pupil
Colbert et al. [7]	49	Male	Upper third molar, inferior second molar and inferior canine, left side. Periodontitis.	-	-	Dental extraction	-
Feldman et al. [8]	69	Male	Mandibular dental abscess	<i>Pseudomonas</i>	Ampicillin sulbactam clindamycin; nafcillin, ceftriaxone and metronidazole; heparin	Drainage of the parapharyngeal abscess; dental extraction; the patient was taken to the operating room, intubated, and examined under anesthesia	Good
Jose et al. [9]	60	Male	Upper second molar root, right side. Periapical lesion around the root	<i>Coagulase-negative Staphylococci</i>	Ceftriaxone, vancomycin and steroids	Drainage; root extraction	Considerable improvement in nerve function
Okamoto et al. [10]	64	Female	Inferior canine, left side	-	Broad-spectrum penicillin	-	Considerable improvement in palsies of the left oculomotor and trochlear nerves
	54	Male	Multiple caries and periodontitis	-	-	-	Pain and mild sensory disturbance around the left orbit
Jones and Arnold [11]	54	Female	Inferior first, second and third molars, dental abscess, gross caries	<i>Streptococcus Constellatus</i>	Meropenem and clindamycin. Enoxeparin and low dose aspirin	Drainage of the dental abscess, dental extraction	Left middle cerebral artery infarct causing rightsided neglect, dysphasia, dysphagia, homonymous hemianopia and hemiplegia
Pavlovich et al. [12]	55	Male	Upper tooth fracture, periodontal disease	<i>Streptococcus Anginosus</i>	Vancomycin, ceftriaxone, metronidazole, penicillin, tinzaparin	-	Good
Verma et al. [13]	50	Female	Upper molars, right side	<i>Staphylococcus Aureus</i>	Vancomycin, ceftriaxone, clindamycin, enoxaparin	Drainage; dental extraction	Good
Yeo et al. [14]	65	Male	Three teeth on the right mandibular side and the left buccal cheek was swollen with a 1 cm laceration.	<i>Staphylococcus Aureus</i>	Ceftazidime, vancomycin, nafcillin	Drainage of the buccal and pterygomandibular spaces	Good
Yun et al. [15]	60	Male	Pus from the upper right third molar tooth	<i>Pseudomonas Aeruginosa</i> and <i>Enterococcus</i>	Vancomycin, ticarcillin plus gentamicin, heparin	Incision and drainage were done on the right buccal area and preauricular region	Persistent paralysis of the right extraocular muscles
Udaondo et al. [16]	51	Female	Two teeth infected	<i>Streptococcus Milleri</i>	Metronidazole and ceftriaxone	Abscess drainage	Good with left sixth cranial nerve paresis
Li et al. [17]	36	Male	Upper third molar region	-	Vancomycin, ceftazidime, heparin	-	Good
Umamaheswara et al. [18]	55	Male	Alveolar abscess in region of the second upper premolar, left side	-	-	Abscess drainage. Emergency surgery for decompression was performed	Death
Alwraikat et al. [19]	7	Male	Dental abscess in right maxillary deciduous molars and in right mandibular first molar	-	Ceftazidime, Metronidazole, Dexamethasone, Heparin	Abscess drainage; dental extraction	Death

(-) not reported.

Cavernous sinus thrombosis

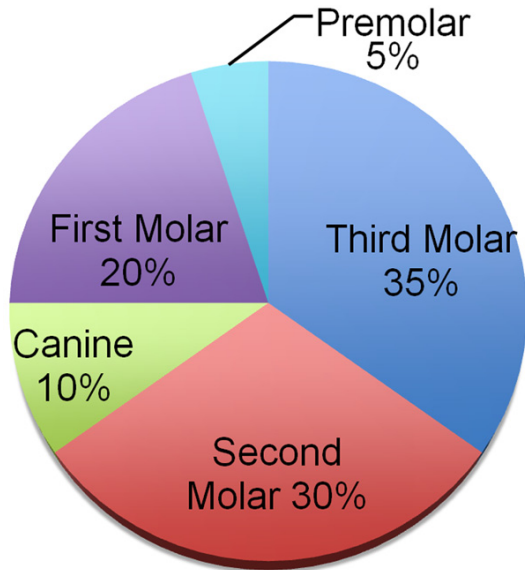


Figure 2. Percentage of primary dental focus from dental abscess.

21.43%, submandibular 7.14% and temporal 7.14%.

Patient's recovery

There was good recovery in 40% of the patients, 46.6% presented sequelae, permanent or otherwise, such as: palsies of the oculomotor and trochlear nerves, pain and mild sensory disturbance around the orbit remained, paralysis of the extraocular muscles and middle cerebral artery infarct. There were 2 patients who died (13.4%).

Discussion

Septic CST is an encephalic complication of pre-existing cranial, cervical or facial infections [1]. The primary source can be acute sinusitis, dacryocystitis, otitis, postoperative infections in the maxillofacial region, skin infections or fungal infections [14]. It is estimated that around 7% of septic CST is of dental origin [20]. One condition must be considered, in which the infection is determined by trauma caused by a dental procedure that occurs when the pterygoid plexus is contaminated by a needle incorrectly inserted during the posterior superior alveolar nerve block [1]. This accident can happen due to the communication between the cavernous sinus and the pterygoid plexus that is formed by a network of veins located in the

infratemporal fossa posterior to the highest part of the maxillary tuberosity.

Clinical diagnosis of septic CST, despite its peculiar characteristics, is difficult in light of its similarity with some infections of the orbit, since the same anatomical structures are involved in both pathologies. The clinical characteristics of septic CST are the same as those observed in any infectious process, i.e., fever, nausea, vomiting, dehydration, prostration. In addition, there are other characteristics related to the anatomical structures associated with the cavernous sinus, such as ophthalmoplegia, proptosis, conjunctival chemosis, diplopia, photophobia, palpebral edema, retro-orbital headache, loss of visual acuity, reduction in pupillary reflexes, anesthesia of the innervation territories of the ophthalmic and maxillary nerves, facial paralysis and meningitis [21-26]. For Di Nubile [27], headache is the most common symptom, usually preceding fevers, periorbital swelling and cranial nerve signs; in our study the most frequently encountered characteristics were swelling, followed by fever, palsy of the cranial nerve (III, IV and VI), proptosis, ptosis, chemosis, headache and pain.

To confirm the diagnosis, computed tomography with contrast can be indicated, which reveals the thrombi inside the sinuses of the dura mater [28]. Some authors consider nuclear magnetic resonance (NMR) the examination of choice in the diagnosis of septic CST [15, 29].

In our study, we found that the primary source also appeared in the mandible and maxilla, there being no tendency toward a side (right/left). The dental focus arose more frequently from a dental abscess, with the third molar being the most affected tooth in 35% of the cases; poor oral hygiene of patients with a high rate of caries was also reported. According to Alves and Cândido [1], the infections that affect the third molar progress towards the submandibular or pterygomandibular space, which communicates with the parapharyngeal space of the neck. This, according to these authors, explains the spread of Ludwig's angina, cellulitis of the submandibular space, towards the parapharyngeal space. We agree with their assessment that this is an emergency situation requiring immediate attention, as the patient

Cavernous sinus thrombosis

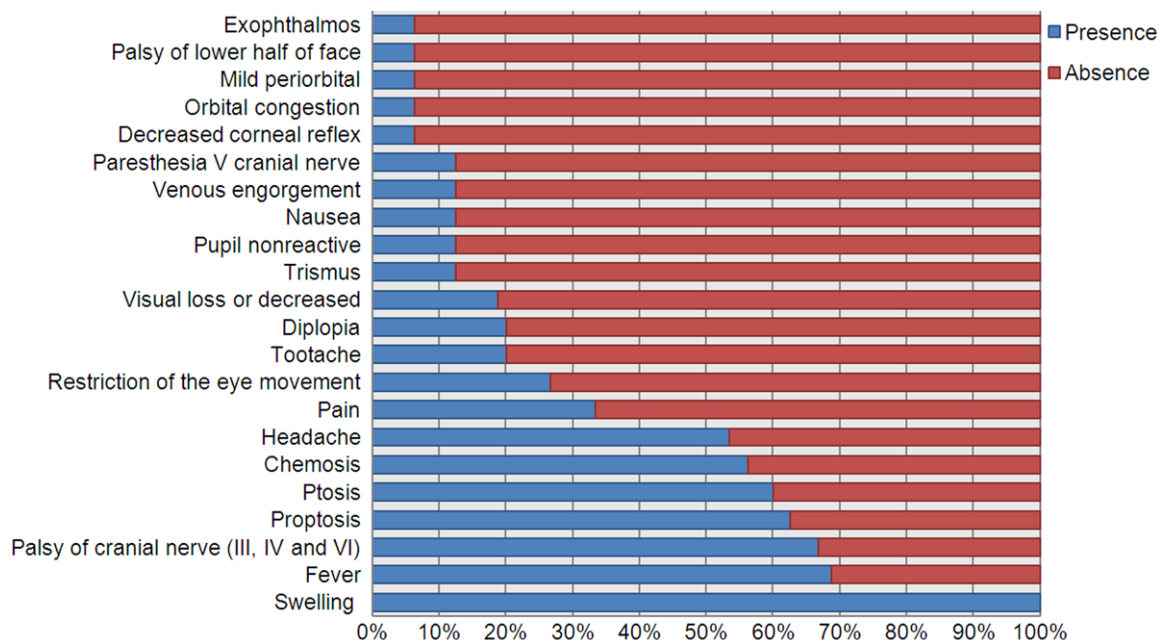


Figure 3. Frequency of symptoms (%) reported according to the studies.

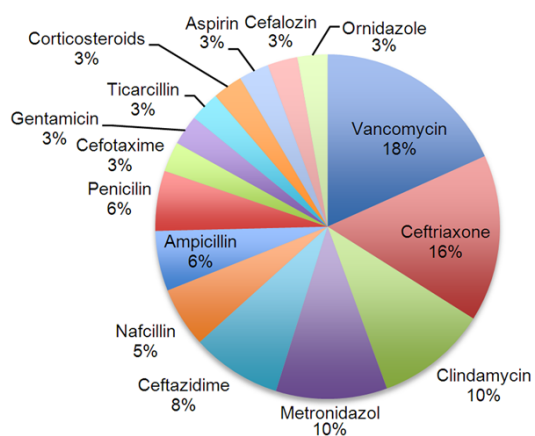


Figure 4. Percentage (%) of use of drugs according to the studies.

can reach a total obstruction of the respiratory tract with asphyxia and death.

The signs of septic CST must be recognized early and its treatment must be started as soon as possible [30] with broad-spectrum antibiotics in high doses. The use of vancomycin and third-generation cephalosporins associated with metronidazole or chloramphenicol are recommended [20, 31-33]. Another route usually taken is antibiotic therapy in accordance with the result of the culture and antibiogram [34]. In our study, we observed that the

drugs were administered in combination and that vancomycin and ceftriaxone were the most frequently used. The use of anticoagulants is indicated to prevent the formation of thrombi in other sinuses [20, 27, 35]; however, according to Thatai et al. [26], they can produce a cerebrovascular accident; in our study we found that 43.75% of the patients had received doses of anticoagulants.

Although Thatai et al. [26] and Southwick et al. [36] report that *staphylococcus aureus* represents 70% of the infectious agents of septic CST, we found only 16.68% of infections due to *staphylococcus aureus*. Other infectious agents such as *pseudomonas (aeruginosa)*, *streptococcus (anginosus, milleri and constellatus)* and *coagulase-negative staphylococci* were also found.

Septic CST can present certain complications. According to some authors, the infection can spread to the extra and subdural spaces, to the leptomeninges and adjacent brain, and to other venous sinuses [37, 38]. In our study, we also observed that dissemination of the infection can spread to multiple spaces, the pterygomandibular and infratemporal being the most common. After septic CST, lesions such as mycotic aneurysms can occur in the intracavernous portion of the internal carotid artery

Cavernous sinus thrombosis

Table 2. Dissemination of the infection by spaces according to the studies analyzed

Authors	Space of dissemination
Kiddee et al. [5]	Pterygomandibular, parapharyngeal and infratemporal spaces
Prabhu et al. [6]	Infratemporal, submandibular, pterygomandibular and buccal spaces
Feldman et al. [8]	Parapharyngeal space
Yeo et al. [14]	Buccal, pterygomandibular and temporal spaces
Yun et al. [15]	Buccal, infratemporal and superior parapharyngeal spaces

[39]. Occlusion of the central retinal artery or injuries to the cornea can cause blindness [38, 40]. According to Karlin and Robinson [38], around 50% of the patients who survive septic CST present sequelae, mainly residual lesions of the oculomotor and abducens nerves, a finding consistent with the results found in our study.

The literature review showed that the odontogenic focus occurs most frequently from a dental abscess and is related mainly to the third molar followed by the second molar, there being no tendency toward a side or maxilla/mandible. The infection can spread more frequently to pterygomandibular, infratemporal, parapharyngeal and buccal spaces. Swelling is the most frequent symptom in patients with septic CST. *Pseudomonas aeruginosa* is the most common infectious agent and drug treatment is usually with combined drugs, with vancomycin being the most frequently used. Surgical treatment is for abscess drainage and dental extraction. Patients generally present short-term or permanent sequelae, and fewer than 50% show a complete recovery prior to hospital discharge.

Considering that odontogenic infections can act as primary sources, dentists are among the professionals responsible not only for diagnosis, but also for prophylaxis and referral for specialized medical treatment.

The literature review allows us to conclude that the diagnosis of CST is largely clinical, and confirmed by imaging. Although CST is a difficult pathology to diagnose, its clinical symptomatology is very well known. The literature also shows that identifying the primary source of infection is fundamental to establishing the initial antibiotic therapy, until the result of the culture and antibiogram are obtained.

Disclosure of conflict of interest

None.

Address correspondence to: Dr. Nilton Alves, CIMA Research Group, Faculty of Dentistry, Universidad de La Frontera, Francisco Salazar Avenue, 1145, Casilla 54-D, Temuco, Chile. Tel: 056-0452325775; E-mail: niltonnalves@yahoo.com.br

References

- [1] Alves N and Cândido PL. Anatomía para o curso de odontología geral e específica. 3rd edition. São Paulo, Brazil: Gen-Santos; 2012.
- [2] Sicher H and DuBrull EL. Anatomia oral. 8th edition. São Paulo, Brazil: Artes Médicas; 1991.
- [3] Testut L and Latarjet A. Anatomia humana. 9th edition. Barcelona, Spain: Salvat; 1954.
- [4] Scrimgeour EM, Alemaena OK and Salomon B. Cavernous sinus thrombosis in two Papua New Guineans. Trop Geogr Med 1985; 37: 194-197.
- [5] Kiddee W, Preechawai P and Hirunpat S. Bilateral septic cavernous sinus thrombosis following the masticator and parapharyngeal space infection from the odontogenic origin: a case report. J Med Assoc Thai 2010; 93: 1107-1111.
- [6] Prabhu S, Jain SK, and Dal Singh V. Cavernous sinus thrombophlebitis (sans thrombosis) secondary to odontogenic fascial space infection: an uncommon complication with unusual presentation. J Maxillofac Oral Surg 2015; 14 Suppl 1: 168-172.
- [7] Colbert S, Cameron M and Williams J. Septic thrombosis of the cavernous sinus and dental infection. Br J Oral Maxillofac Surg 2011; 49: e25-e26.
- [8] Feldman DP, Picerno NA and Porubsky ES. Cavernous sinus thrombosis complicating odontogenic parapharyngeal space neck abscess: a case report and discussion. Otolaryngol Head Neck Surg 2000; 123: 744-745.
- [9] Jose A, Nagori SA, Bhutia O and Roychoudhury A. Odontogenic infection and pachymeningitis of the cavernous sinus. Br J Oral Maxillofac Surg 2014; 52: e27-e29.
- [10] Okamoto H, Ogata A, Kosugi M, Takashima H, Sakata S and Matsushima T. Cavernous sinus thrombophlebitis related to dental infection: two case report. Neurol Med Chir (Tokyo) 2012; 52: 757-760.

Cavernous sinus thrombosis

- [11] Jones RG and Arnold B. Sudden onset proptosis secondary to cavernous sinus thrombosis from underlying mandibular dental infection. *BMJ Case Rep* 2009.
- [12] Pavlovich P, Looi A and Rootman J. Septic thrombosis of the cavernous sinus: two different mechanisms. *Orbit* 2006; 25: 39-43.
- [13] Verma R, Junewar V, Singh RK, Ram H and Pal US. Bilateral cavernous sinus thrombosis and facial palsy as complication of dental abscess. *Natl J Maxillofac Surg* 2013; 4: 252-255.
- [14] Yeo GS, Kim HY, Kwak EJ, Jung YS, Park HS, and Jung HD. Cavernous sinus thrombosis caused by a dental infection: a case report. *J Korean Assoc Oral Maxillofac Surg* 2014; 40: 195-198.
- [15] Yun MWD, Hwang CF and Lui CC. Cavernous sinus thrombosis following odontogenic and cervicofacial infection. *Eur Arch Otorhinolaryngol* 1991; 248: 422-424.
- [16] Udaondo P, Garcia Delpech S, Díaz-Llopis M, Salom D and Strottmann JM. Bilateral intraorbital abscesses and cavernous sinus thrombosis secondary to *Streptococcus milleri* with a favorable outcome. *Ophtal Plastic Reconstr Surg* 2008; 24: 408-410.
- [17] Li Y, Zheng B, Chen K and Gui L. Successful treatment of dental infection-induced chronic cavernous sinus thrombophlebitis with antibiotics and low-molecular-weight heparin: two case reports. *J Oral Maxillofac Surg* 2015; 73: 1516-1523.
- [18] Umamaheswara RV, Agrawal A, Hegde KV, Srikanth V and Sahith RK. Massive infarction and cavernous sinus thrombosis: an uncommon complication of tooth extraction. *Romanian Neurosurg* 2014; 21: 501-505.
- [19] Alwraikat AA and Alawneh HI. Cavernous sinus thrombosis as a fatal complication of a dental abscess: a case report. *J Royal Med Serv* 2010; 17: 20-23.
- [20] Bhatia K and Jones NS. Septic cavernous sinus thrombosis secondary to sinusitis: are anticoagulants indicated? A review of the literature. *J Laryngol Otol* 2002; 116: 667-676.
- [21] Chacar-Rabay H, Hejeily RK and Aouad A. Thrombose du sinus caveux retard au diagnostic et complications. *J Med Leban* 1998; 46: 218-221.
- [22] Estrem SA, Tully R and Davis WE. Rhinocerebral mucormycosis: computed tomographic imaging of cavernous sinus thrombosis. *Ann Otol Rhinol Laryngol* 1990; 99: 160-161.
- [23] Palmersheim LA and Hamilton MK. Fatal cavernous sinus thrombosis secondary to third molar removal. *J Oral Maxillofac Surg* 1982; 40: 371-376.
- [24] Sofferman RA. Cavernous sinus thrombophlebitis secondary to sphenoid sinusitis. *Laryngoscope* 1983; 93: 797-800.
- [25] Taicher S, Garfunkel A and Feinsod M. Reversible cavernous sinus involvement due to minor dental infection: Report of a case. *Oral Surg Oral Med Oral Pathol* 1978; 46:7-9.
- [26] Thatai D, Chandy L and Dhar KL. Septic cavernous sinus thrombophlebitis: a review of 35 cases. *J Indian Med Assoc* 1992; 90: 290-292.
- [27] DiNubile MJ. Septic thrombosis of the cavernous sinuses. *Arch Neurol* 1988; 45: 567-572.
- [28] Babin E, Ndyaye M, Bequignon A, Vadillo M, Moreau S, Valzade A, Jokic M, Coskun O and Hamon M. Otogenic cavernous sinus thrombophlebitis. A case report. *Ann Otolaryngol Chir Cervicofac* 2003; 120: 237-243.
- [29] Igarashi H, Igarashi S, Fujio N, Fukui K and Yoshida A. Magnetic resonance imaging in the early diagnosis of cavernous sinus thrombosis. *Ophthalmologica* 1995; 209: 292-296.
- [30] Swaminath D, Narayanan R, Orellana-Barrios MA and Temple B. Necrotizing Fasciitis of the nose complicated with cavernous sinus thrombosis. *Case Rep Infect Dis* 2014; 2014: 914042.
- [31] Coll GE, Boxrud CA, Steinsapir KD and Goldberg RA. Septic cavernous sinus thrombosis after head trauma. *Am J Ophthalmol* 1994; 117: 538-539.
- [32] Sadun F, Feldon SE, Weiss MH and Krieger MD. Septic cavernous sinus thrombosis following transsphenoidal craniotomy. *Case Report. J Neurosurg* 1996; 85: 949-952.
- [33] Kalangu KK. Cavernous sinus thrombosis: a report for eight consecutive comatose patients. *East Afr Med J* 1995; 72: 791-795.
- [34] Gallagher RM, Gross CW and Phillips D. Suppurative intracranial complications of sinusitis. *Laryngoscope* 1998; 108: 1635-1642.
- [35] Stam J, De Bruijn SF and DeVeber G. Anticoagulation for cerebral sinus thrombosis. *Cochrane Database Syst Rev* 2002; CD002005.
- [36] Southwick FS, Richardson EP Jr and Swartz MN. Septic thrombosis of the dural venous sinuses. *Medicine (Baltimore)* 1986; 65: 82-106.
- [37] Bennett JC and Plum F. Cecil textbook of medicine. 20th edition. Philadelphia: Saunders; 1996.
- [38] Karlin RJ and Robinson WA. Septic cavernous sinus thrombosis. *Ann Emerg Med* 1984; 13: 449-455.
- [39] Rout D, Sharma A, Mohan PK and Rao VR. Bacterial aneurysms of the intracavernous carotid artery. *J Neurosurg* 1984; 60: 1236-1242.
- [40] Lloyd GA. The localization of lesions in the orbital apex and cavernous sinus by frontal venography. *Br J Radiol* 1972; 45: 405-414.